

# EXACTECH | SHOULDER

Operative Technique

Addendum to the Equinox Reverse Operative Technique



**equinox**<sup>®</sup>  
SHOULDER SYSTEM

**Reverse Superolateral  
Approach**

## TABLE OF CONTENTS

<b>INTRODUCTION</b> .....	1
<b>OPERATIVE TECHNIQUE OVERVIEW</b> .....	2
<b>DETAILED OPERATIVE TECHNIQUE</b> .....	4
PRE-OPERATIVE PLANNING.....	4
PATIENT POSITIONING .....	4
SURGICAL APPROACH.....	5
HUMERAL PREPARATION.....	6
PREPARING THE GLENOID.....	7
<b>INSTRUMENT LISTING</b> .....	12

### **EQUINOXE® REVERSE SUPEROLATERAL TECHNIQUE:**

**Brian Barnard, MD**

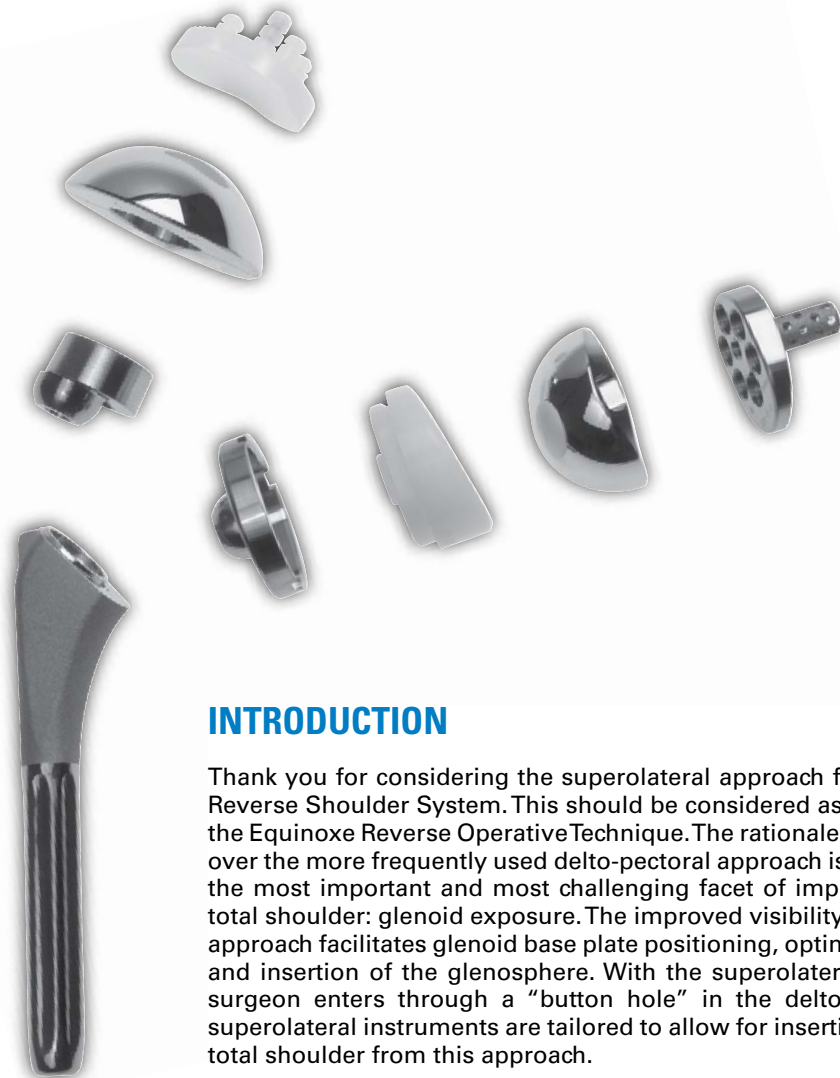### **EQUINOXE® REVERSE SHOULDER SYSTEM DESIGN TEAM:**

**Lynn A. Crosby, MD**

**Pierre-Henri Flurin, MD**

**Thomas W. Wright, MD**

**Joseph D. Zuckerman, MD**



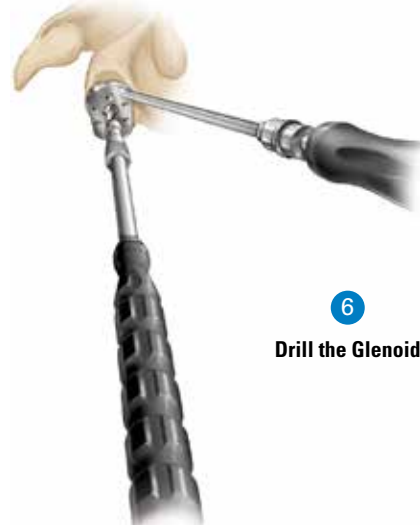
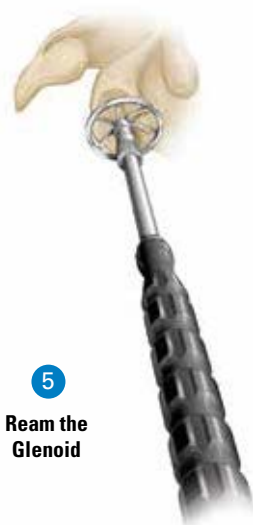
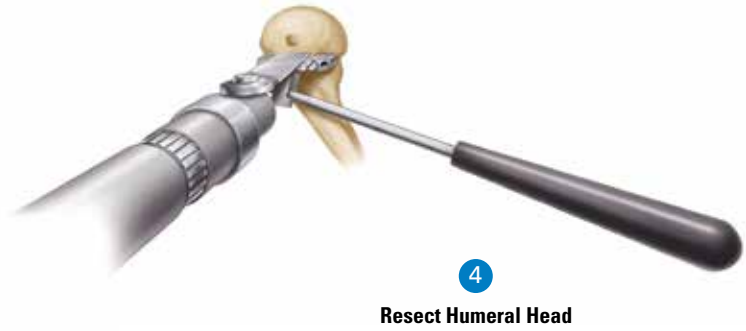
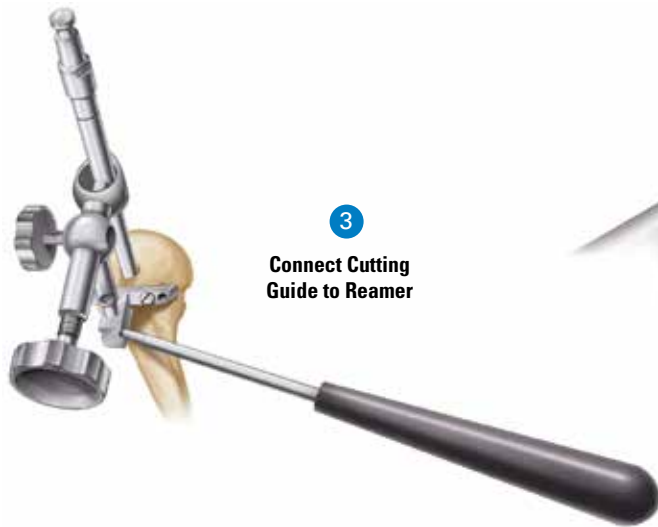
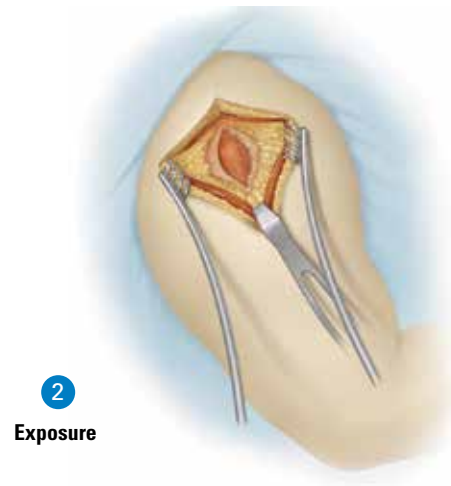
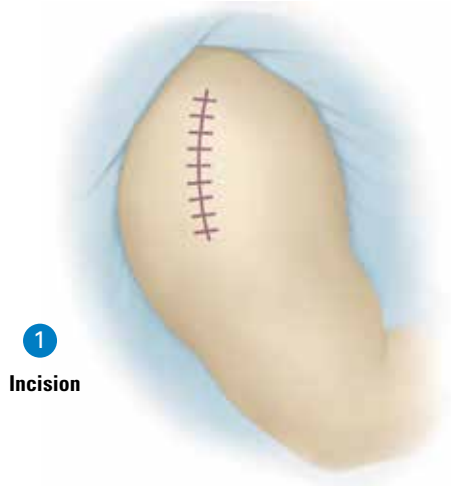## INTRODUCTION

Thank you for considering the superolateral approach for the Equinox® Reverse Shoulder System. This should be considered as a supplement to the Equinox Reverse Operative Technique. The rationale for this approach over the more frequently used delto-pectoral approach is that it prioritizes the most important and most challenging facet of implanting a reverse total shoulder: glenoid exposure. The improved visibility provided by this approach facilitates glenoid base plate positioning, optimal screw fixation and insertion of the glenosphere. With the superolateral technique, the surgeon enters through a “button hole” in the deltoid. The Exactech superolateral instruments are tailored to allow for insertion of the reverse total shoulder from this approach.

Potential situations for the superolateral approach:

- 1) Patients with retroversion of the glenoid, which distorts the orientation of glenoid
- 2) Patients with very osteopenic bone, which renders fixation of the glenoid plate of utmost importance
- 3) Large, muscular patients who make exposing the glenoid more difficult
- 4) Patients with large osteophytes off the surface of the glenoid, which make determining the orientation of the glenoid vault challenging.

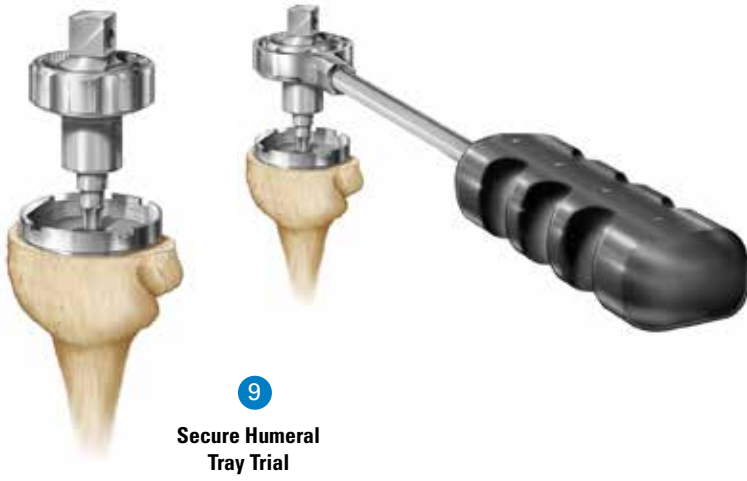
# OPERATIVE TECHNIQUE OVERVIEW



**7**  
Broach the  
Humerus



**8**  
Insert the  
Final Stem



**9**  
Secure Humeral  
Tray Trial

**10**  
Insert the  
Final Humeral  
Adapter Tray



## DETAILED OPERATIVE TECHNIQUE

### PRE-OPERATIVE PLANNING

After a careful history and physical examination, radiographs should be obtained to assess glenohumeral joint space narrowing, osseous deformities and glenoid wear. A CT scan is helpful to assist in the evaluation of the quality of bone stock and to further evaluate bone deformities that may be present. An MRI may be obtained if further evaluation of the soft tissues is determined to be helpful. To aid in pre-operative planning, radiographic templates are provided for the humeral components and glenoid components to approximate the required size and alignment of the implants.

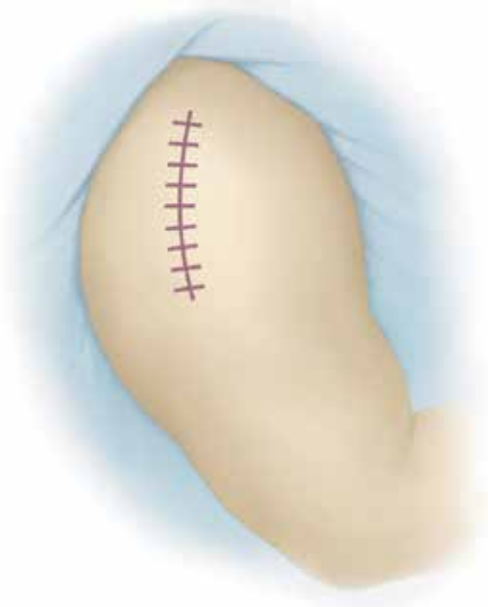The Axillary/AP views are important to evaluate the following:

- 1) Axillary view
  - a. Check the relationship of the glenoid face to the body of the scapula
  - b. Check for size of the glenoid vault
  - c. Check for an Os Acromiale, which might need to be excised or fixated during the procedure.
- 2) AP view
  - a. Check for possible impingement with the neck of the scapula
  - b. Check for possible impingement with osteophytes under the AC joint
  - c. Check for possible impingement with a large acromial spur
  - d. Check the anticipated orientation of the screws for fixation of the Glenoid Plate within the glenoid vault.

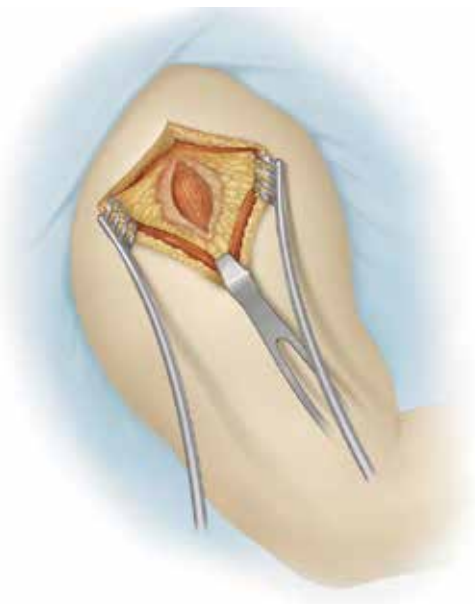
### PATIENT POSITIONING

Utilizing a low profile headrest, the patient should be placed in a beach chair position with the head off the bed slightly more vertical to allow the arm to hang down. The patient should be moved to the side of the operating table with only the scapula on the bed so the arm can hang freely over the edge. Place one or two folded hand towels under the wing blade to stabilize the scapula. Consider taping the patient at chest level to the operating table to minimize any changes in position intra-operatively. A U-drape should then be placed from above to exclude the neck from the field. Use an alcohol-based cleanser to prep the upper extremity before draping and then use a surgical marker to mark the exact incision site. Since the alcohol "sets" the ink, it minimizes accidentally limiting the anticipated operative site before prepping and draping.





**Figure 1**  
Incision



**Figure 2**  
Exposure

## SURGICAL APPROACH

For patients without a large amount of subcutaneous tissue, a 3-inch incision is really all that is needed to comfortably perform the superolateral approach (*Figure 1*). With experience using the Equinox instrumentation and confidence with the approach, the necessary incision will become smaller. Allowing more exposure superomedially, however, will aid in visualization and ease of instrument passage, while extending the incision laterally only encourages propagation in the deltoid muscle split and possible injury to the axillary nerve.

The incision starts just medial to the AC joint, continuing laterally to the edge of the acromion, and then longitudinally down the line of the humerus. Preferably, the exposure on the humeral side should not extend more than 5cm beyond the lateral edge of the acromion since this aids in preventing an unwanted propagation of the deltoid opening (*Figure 2*).

The subcutaneous dissection can be performed with electrocautery down to the periosteum of the clavicle, over the AC joint and the acromion, and exposing the fascia of the deltoid.

Next, incise through the periosteum of the clavicle, over the AC joint to the lateral edge of the acromion, and then longitudinally split the deltoid at the more tendinous interval between the middle and anterior one-thirds. A safe distance for opening the deltoid can be measured from the "drop-off" at the lateral edge of the acromion for a distance of 4cm. A #2 ethibond suture should be placed at the distal edge of the deltoid split to prevent propagation of the deltoid split and risk stretch or injury to the axillary nerve coursing on the underside of the muscle.

A subperiosteal release of the deltoid is performed from the anterior edge of the acromion, and the distal clavicle is exposed. To ensure there is no impingement under a hypertrophic AC joint, a distal clavicle resection can be performed. Also, a resection of an acromial hook can be done as well as performing a subacromial decompression, taking note to resect along a downward slope of the lateral corner of the acromion to prevent impingement of the proximal humerus during flexion.

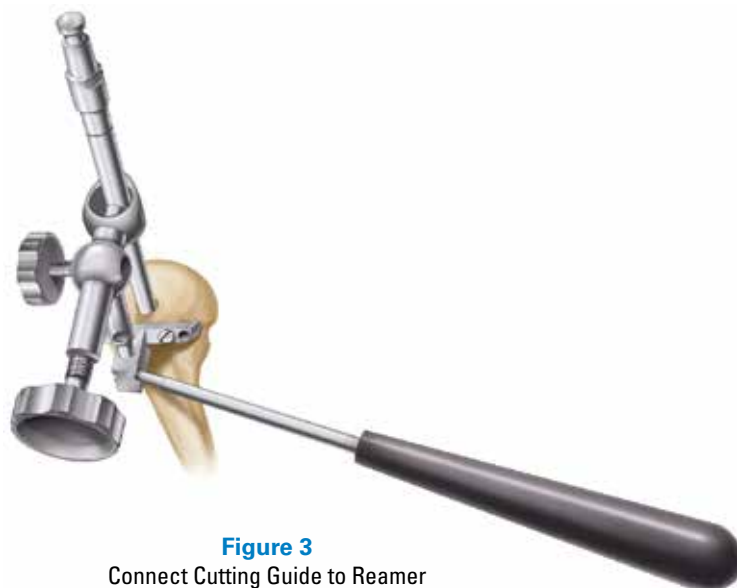
## HUMERAL PREPARATION

A 90-degree Gelpi or self-retaining retractor offers a nice, low-profile opening of the deltoid window. The humeral head is then elevated into the opening of the deltoid by an assistant. A bent **Hohmann Retractor** aides in retraction of the anterior deltoid, and an **Army/Navy Retractor** helps in pulling the deltoid over the greater tuberosity, allowing for placement of the humeral cutting jig.

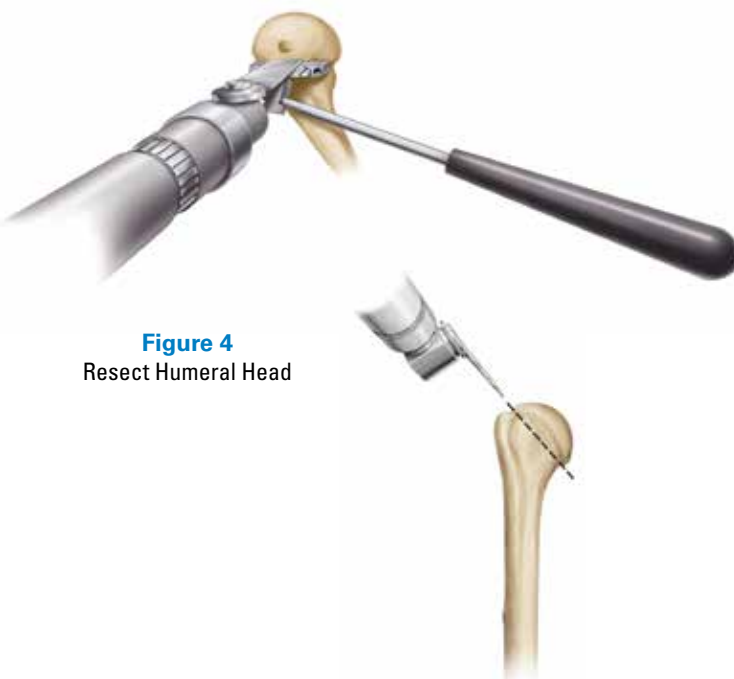
The 7mm starter reamer for the Exactech reverse shoulder can be tapped into the humeral head in line with the humerus and then seated in the shaft. The **Superolateral IM Cutting Guide** is then connected to the reamer at a level just distal to the greater tuberosity aligning with the anatomic neck of the humerus (*Figure 3*).

The **Drill Guide Handle** is then threaded into the anterior face of the Superolateral Cutting Guide and is aligned with the forearm. The Superolateral Cutting Guide can then be fixed to the humeral head using 1/8-inch locking pins from the reamer and IM jig to be removed from the Cutting Guide so that the humeral head can be resected (*Figure 4*).

A sagittal saw is placed on the Superolateral Cutting Guide to resect the humeral head. Care should be taken when resecting the outer cortex of the humeral head to avoid diving deep into the medial soft tissues, which harbor vascular tissues and the axillary nerve. After the humeral head is resected, remove the locking pins and the Superolateral Cutting Guide. A bent Hohmann Retractor can be used to expose the interface of the soft tissue attachments to the humeral head. Using electrocautery and with rotation of the shoulder for better visualization, the humeral head can be easily removed, giving the first view of the glenoid face.

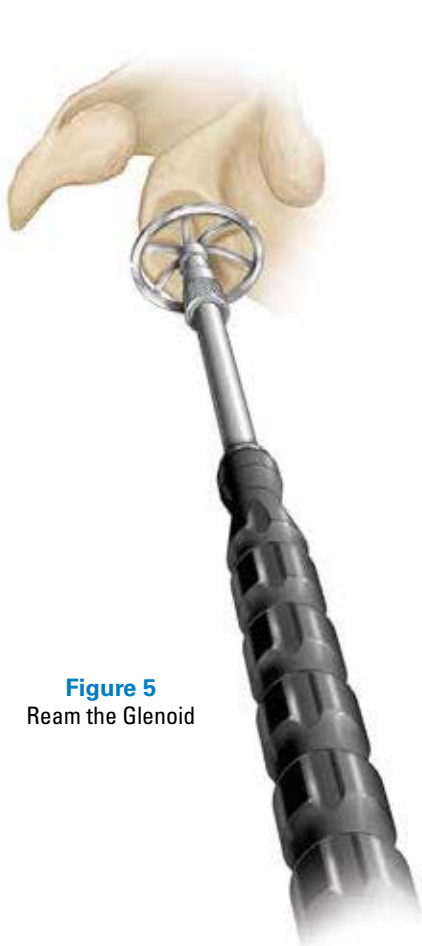


**Figure 3**  
Connect Cutting Guide to Reamer



**Figure 4**  
Resect Humeral Head





**Figure 5**  
Ream the Glenoid

## PREPARING THE GLENOID

In order to improve visualization of the glenoid, the lateral edge of the humerus can be resected. This also minimizes impingement of the lateral edge of the humerus on the undersurface of the acromion once the implant is in place. The humeral stem protector can then be placed on the cut surface of the humerus.

The improved visualization of the glenoid can be obtained by placing the two prongs of the small **Forked Retractor** under the inferior lip of the glenoid, and depressing the protected end of the humerus. Airplaning the O.R. table away from the surgeon improves the orientation for instrumentation and also improves surgical light penetration.

Once the glenoid is in full view, a systematic removal of any remaining glenoid labrum should be performed. While removing the labrum, care should be taken not to venture away from the bony edge of glenoid, especially inferiorly, where the axillary nerve might be encountered. Using electrocautery might alert the surgeon to the proximity of the axillary nerve if a muscular twitch is felt. Once the labrum has been removed, a curved **Periosteal Elevator** or **Crego Retractor** can be used to feel around the anterior and posterior edges of the glenoid. This will help gain orientation to the location and size of the glenoid vault, and warn of large osteophytes extending around the rim of the glenoid.

The centering guide for the glenoid plate is now placed on the face of the glenoid. Align the inferior aspect of the **Modular Superiorlateral Glenoid Plate Drill Guide** with the inferior aspect of the native glenoid bone after removing any inferior glenoid osteophytes. This ensures the glenosphere is properly positioned in a superior-inferior position. Palpate the anterior glenoid neck to determine the angle for glenoid reaming (*Figure 5*).

**Note:** While the Equinox Glenoid Plate does not need to be inferiorly tilted or angled, it should not be implanted with a superior tilt. A neutral orientation is ideal.

If there is excessive retroversion of the glenoid relative to the body of the scapula (i.e. posterior glenoid wear), the surgeon should reorient the reaming, as much as allowed by the size of the glenoid vault. This should help prevent the screws from perforating the anterior cortex of the glenoid and aiming toward the chest wall.

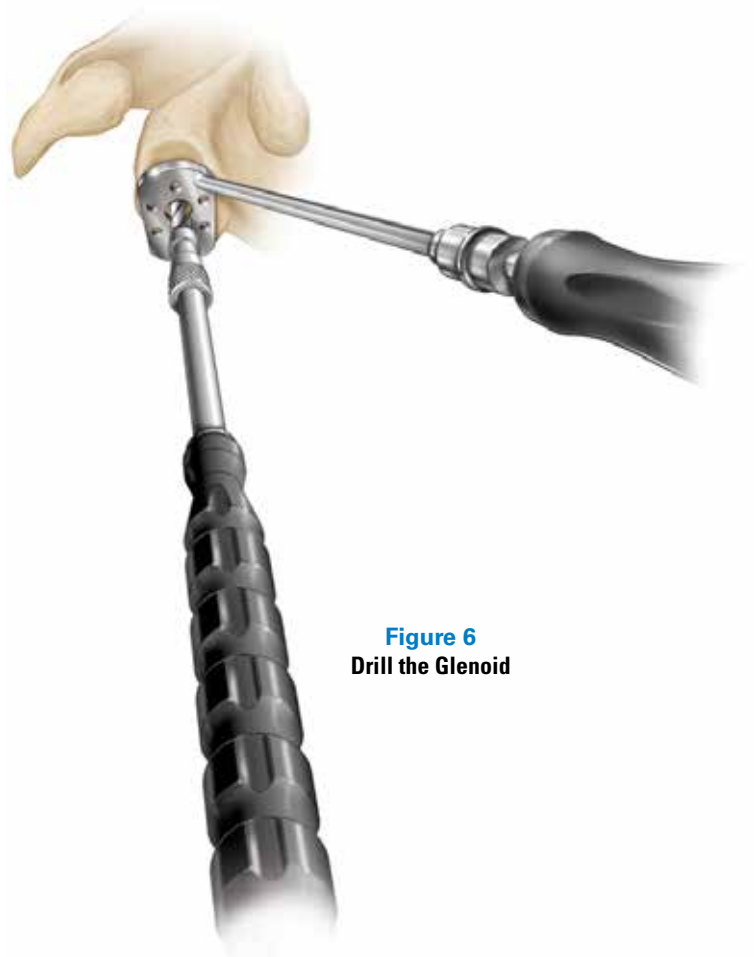
Cannulated instruments are available to aid the surgeon in glenoid preparation. If the cannulated instruments are selected, the cannulated reamers are inserted over a 2mm (.079 inch) K-wire.

The glenoid is sequentially reamed until any pre-identified glenoid erosions are corrected and the glenoid surface has been fully contoured. It is critical to ream to the size of the largest potential Glensphere that the surgeon might use to ensure that the Glensphere will fit on the face of the glenoid. The desired size of the Glensphere should be correlated to the expected size noted on X-ray templating, but should avoid impingement at the inferior edge of the glenoid or the neck of the scapula. By looking through the spokes of the reamer, the surgeon can ensure that a congruous match will be obtained for the undersurface of the Glenoid Plate.

After reaming has been completed, the inferior aspect of the **Modular Superiorlateral Glenoid Plate Drill Guide** is realigned with the inferior aspect of the glenoid. Connect the **Modular Superiorlateral Glenoid Plate Drill** to the **Modular Driver** to prepare the glenoid for the cage hole of the Glenoid Plate (*Figure 6*). The Glenoid Plate Drill is 7.3mm in diameter. The Glenoid Plate cage is tapered and varies in diameter between 7.5mm at its end to 8.1mm where it joins the back of the Glenoid Plate.

**Note:** Modular Cannulated Center Peg Drill Option: After reaming over the 0.079 inch K-wire, drill over the existing K-wire with the Modular Cannulated Center Peg Drill.

**Note:** Avoid applying a bending force to the pilot tip reamer or using the reamer to retract the humeral head as this may cause fracture of the 2mm K-wire or pilot tip.



**Figure 6**  
**Drill the Glenoid**

**Figure 7**  
Broach the Humerus



Using the **Glenoid Plate Inserter** for rotational control, the Glenoid Plate (with bone graft filling the cage) is impacted against the reamed surface of the glenoid. It has been found that, while a small Forked Retractor can help to ensure good exposure, it is easier to impact the Glenoid Plate by first removing the inferior retractor once the central peg has been started into its hole. Brisk impaction is then performed perpendicular to the face of the glenoid. The surgeon can confirm proper seating of the Glenoid Plate by peering through the screw holes.

Keeping in mind the overall teardrop shape of the glenoid, the surgeon should place at least four screws for fixation of the Glenoid Plate. Once the compression screws have been seated, the locking caps are placed. Although the Glenosphere may be placed at this time, it is recommended that it be delayed until after the humeral component has been inserted to allow easier access to the proximal humerus.

The surgical assistant can now elevate the humerus into the buttonhole of the deltoid. The humerus is reamed in sequential 2mm steps to a snug fit, and then broached proximally for rotational stability (*Figure 7*).

The **Humeral Stem Trial** can now be inserted using the **Primary Stem Inserter** (*Figure 8a*). The Humeral Stem Trial is then unthreaded from the Primary Stem Inserter using the **Square Drive** and/or **Square Drive with Thumbwheel** (*Figure 8b*). The Glenosphere Trial or glenosphere can now be inserted if not done previously. Next, the **Humeral Tray Trial** is assembled to the Humeral Stem Trial with the **3.5mm Hex** and/or **3.5mm Hex with Thumbwheel** (*Figure 9a*). The **Breakoff Wrench** may also be used around the **Thumbwheel** to facilitate tightening of the tray if so desired (*Figure 9b*). After securing the Tray Trial, the **Humeral Liner Trial** should be assembled, and the joint can be reduced to assess range of motion and stability.

While each surgeon may have their own system to assess stability, we approach the trial reduction as follows:

- 1) When traction is applied to the arm with the shoulder in flexion, there should be no separation or gap between the Glenosphere and the Humeral Liner
- 2) With adduction of the shoulder and a laterally directed force from the axilla, there should be no dislocation of the implant
- 3) With flexion of the shoulder, the greater tuberosity should not impinge on the anterior or lateral edges of the acromion
- 4) The arm should easily be able to come to the chest as well as to reach across the body to the opposite shoulder.

Once the proper selection is made of the Humeral Adapter Tray Trial and Humeral Liner Trials, the trial implants are removed and the wound is thoroughly irrigated. The appropriate sized humeral stem is then cemented at the appropriate height. Next, the final Glenosphere should be inserted and then secured with the **Glenosphere Locking Screw**.

**Figures 8a and 8b**  
Insert the Final Stem



**Figures 9a and 9b**  
Secure Humeral Tray Trial





**Figures 10a and 10b**  
Insert the Final Humeral  
Adapter Tray

The Humeral Adapter Tray and Humeral Liner Trials may be retested if any doubt exists related to the tension and stability of the implant. The final humeral adapter tray is then affixed to the humeral stem using the **Reverse Shoulder Torque Defining Screw**. The Torque Defining Screw is tightened to the humeral stem with the square drive and thumbwheel (*Figure 10a*). Once the Torque Defining Screw is fully tightened, the counter torque handle is secured within the humeral tray to provide the counter-torque as the breakoff wrench is placed over the thumbwheel and used to tighten the screw to 11 Nm (*Figure 10b*). The superior portion of the screw will disengage when 11 N\*m is reached. The definitive humeral liner is then impacted using the impactor handle. At this point the humeral component should be reduced. Range of motion and stability should be assessed to confirm the findings from the trial reduction. Once this assessment has been made, closure can be performed.

The deltoid is securely sutured into the bone of the anterior acromion using #2 ethibond sutures. Similarly, the periosteum of the distal clavicle and the fascia of the deltoid are closed over a hemovac drain.

**Note:** Impact the T-handle with a Mallet to ensure the driver is fully engaged in the screw. Failure to fully engage the UHMWPE plug on the screw head may prevent the screw head from being retained by the torque defining screw driver.

# INSTRUMENT LISTING

**Catalog Number Part Description**

311-01-11 IM Humeral Cutting Guide



311-01-13 Superior Lateral IM Humeral Cutting Guide



321-10-40 Superior Lateral Counter Torque Handle



321-10-41 Breakoff Wrench



321-10-43 Thumbwheel



321-15-19 3.5mm Hex Drive, 3/8 Wrench Connection



321-15-21 Square Drive, 3/8 Wrench Connection



321-15-30 Modular Glenoid Plate Drill Guide, Superior Lateral, Left



321-15-31 Modular Glenoid Plate Drill Guide, Superior Lateral, Right






Exactech is proud to have offices and distributors around the globe.  
For more information about Exactech products available in your country, please visit [www.exac.com](http://www.exac.com)

---

For additional device information, refer to the Exactech Equinox® Reverse—Instructions for Use for a device description, indications, contraindications, precautions and warnings. For further product information, please contact Customer Service, Exactech, Inc., 2320 NW 66th Court, Gainesville, Florida 32653-1630, USA. (352) 377-1140, (800) 392-2832 or FAX (352) 378-2617.

Exactech, as the manufacturer of this device, does not practice medicine, and is not responsible for recommending the appropriate surgical technique for use on a particular patient. These guidelines are intended to be solely informational and each surgeon must evaluate the appropriateness of these guidelines based on his or her personal medical training and experience. Prior to use of this system, the surgeon should refer to the product package insert for comprehensive warnings, precautions, indications for use, contraindications and adverse effects.

The products discussed herein may be available under different trademarks in different countries. All copyrights, and pending and registered trademarks, are property of Exactech, Inc. This material is intended for the sole use and benefit of the Exactech sales force and physicians. It should not be redistributed, duplicated or disclosed without the express written consent of Exactech, Inc. ©2015 Exactech, Inc.

 CE Mark is not valid unless there is a CE Mark on the product label.  
2797

352-377-1140 • 1-800-EXACTECH • [www.exac.com](http://www.exac.com)

 **Exactech**<sup>®</sup>  
Surgeon focused. Patient driven.